



International Journal of Primary and Secondary Research (IJPSR)

International, Double-Blind, Quarterly, Peer-Reviewed, Refereed,
 Edited and Open Access Research Journal
 Journal homepage: ijpsr.co.in



Protective Efficacy of Vitamin E Against Triazine-Induced Hepatic Damage in Freshwater Fish *Channa punctatus* (Bloch.)

Sheetal Rajput^{*1}, Harendra Nath Sharma², Harendra Gaur¹ and Mohd Shoeb³

¹Department of Zoology, Shri Varshney College, Aligarh, Affiliated to Raja Mahendra Pratap Singh University, Aligarh, Uttar Pradesh, India

²Department of Zoology, Agra College Agra, Affiliated to Dr. Bhimrao Ambedkar University, Agra, Uttar Pradesh, India

³Department of Zoology, Gandhi Faiz e Aam College, Shahjahanpur, Uttar Pradesh, India

* Corresponding author. E-mail address: sheetalrajput10feb@gamil.com

DOI- <https://doi.org/10.59436/ijpsr.v2i2.1.3139-342X>

ARTICLE INFO

Article history:

Received 01 March 2026

Received in revised form

April 2026

Accepted 20 May 2026

Available online 14 June 2026

Keywords:

Channa punctatus,
 Triazine herbicide,
 Hepatotoxicity,
 Vitamin E,
 Liver biomarkers,
 Histopathology,
 Oxidative stress

ABSTRACT

The widespread use of triazine herbicides in modern agriculture has resulted in increasing contamination of aquatic ecosystems, posing significant risks to non-target aquatic organisms, particularly fish. The present study was undertaken to evaluate the hepatotoxic effects of triazine herbicide exposure on the freshwater fish *Channa punctatus* (Bloch.) and to investigate the protective efficacy of Vitamin E against pesticide-induced liver damage. Healthy fish were exposed to a sublethal concentration of triazine herbicide for 30 days, while a separate treatment group received dietary supplementation of Vitamin E in addition to triazine exposure. Hepatic toxicity was assessed through biochemical analyses of liver function biomarkers, including alanine aminotransferase (ALT), aspartate aminotransferase (AST), alkaline phosphatase (ALP), acid phosphatase (ACP), lactate dehydrogenase (LDH), total protein, albumin, globulin, and bilirubin. Histopathological examination of liver tissues was also performed to evaluate structural alterations. The results revealed significant increases in ALT, AST, ALP, ACP, LDH, and bilirubin levels in triazine-exposed fish compared with the control group, indicating severe hepatocellular damage and impaired liver function. Conversely, total protein, albumin, and globulin concentrations were significantly reduced, reflecting disruption of hepatic synthetic activity. Histological observations further confirmed liver injury, characterized by hepatocellular degeneration, cytoplasmic vacuolation, nuclear pyknosis, sinusoidal dilation, congestion, and disorganization of hepatic cords. These findings demonstrate that triazine exposure induces substantial biochemical and structural alterations in the liver of *Channa punctatus*. Vitamin E supplementation markedly ameliorated the toxic effects of triazine by restoring altered biochemical parameters toward normal levels and reducing the severity of histopathological lesions. The antioxidant properties of Vitamin E likely contributed to the stabilization of cellular membranes, inhibition of lipid peroxidation, and reduction of oxidative stress-induced tissue damage. Improved hepatic architecture and recovery of liver function biomarkers in the Vitamin E-treated group further confirmed its hepatoprotective potential. triazine herbicide causes significant hepatotoxicity in *Channa punctatus*, whereas Vitamin E provides effective protection against pesticide-induced liver damage. The study highlights the importance of antioxidant-based interventions in mitigating environmental toxicant-induced stress and provides valuable insights into the management of pesticide contamination in aquatic ecosystems.

Introduction

Aquatic ecosystems are increasingly being threatened by anthropogenic pollutants originating from agriculture, industry and domestic activities, and pesticides constitute one of the most ubiquitous environmental contaminants considered hazardous by the United Nations. Pesticides are chemicals that are used to control biological, insect and weed infestations in crops, extensively used since the middle of the 20th century and thus of environmental concern (Goldberg *et al.*, 2015; Koutnik *et al.*, 2015). Obviously pesticides reach aquatic environments mostly via runoff, but also by leaching, spray drift and improper disposal (elimination) (Koutnik *et al.*, 2015). Rivers, lakes, reservoirs and ponds become polluted with pesticide residues (Koutnik *et al.*, 2015). Of the different classes of pesticides in use triazine herbicides are among the most widely used agrochemicals in the world (Velisek *et al.*, 2011). Atrazine, simazine and propazine are commonly used to control weeds in maize, sorghum, sugarcane and wheatcrops (Velisek *et al.*, 2011). These chemicals have moderate water solubility, high

environmental persistence, and considerable mobility (Velisek *et al.*, 2011). As a result of their use surface waters and sediments in many agricultural are found contaminated with them. These triazines remain in aquatic environments for extended periods of time as they are resistant to decomposition (Hostovsky *et al* 2014), exposing aquatic organisms to active form. Fish are excellent ecoinicators because they occupy various trophic levels and because of their ability to bioaccumulate contaminants from water, sediment and food sources (Austin, 2010). Freshwater species of fish are variously contaminated by travel through a polluted environment. Since fishes are constantly exposed to dissolved materials in the water during respiration and feeding, ecological assessments of toxicity caused by residues left by pesticide exposure require toxicological studies using fish. *Channa punctatus* (Bloch), common name spotted snakehead fish, widely distributed throughout India and other south Asian countries, though not as prestigious as an economic freshwater fish, nevertheless forms an important resource for local use and sources of human food. *Channa punctatus*, commonly known as the spotted snakehead fish, is

used as test fish for experiments, because of its relative abundance in fresh waters, and also because it is very sensitive to substances administering aquatic pollution (Pandey *et al.*, 2005). Experimental work has frequently been conducted using this fish, whose suitability when desired is retained under laboratory conditions, and though a relatively indifferent fall-back test fish, behaves under test conditions according to its need of environmental elements. Work has been conducted using *Channa punctatus* for determining the physiological and biochemical effects of pesticides. The liver plays an important role in fish metabolism and biotransformation of xenobiotics, among other functions such as detoxification, storage, and synthesis of proteins. The liver, being the principal organ of detoxification, is readily impaired against environmental contaminants such as industrial effluents, heavy metals, organocontaminants like pesticides (Paolini *et al.*, 2005). A large amount of literature data reporting that exposures to toxicants can produce hepatic effects has been generated since the time of the publication referred to above. Long term, repeated exposures to contaminants mediate structural derangement and dysfunction of the metabolic machinery of liver cells in establishing biological standards for effect studies in fish; biomarkers of liver function are therefore widely assumed and have been used in toxicity assessments (Brooks *et al.*, 2003). Fishes as “test organisms” lend themselves readily to wide varieties of exposure studies developing information on such things as the role of exogenous factors contributing to metabolic and physiologic derangements due to exposure to triazine herbicides, which have generated a wealth of information pertinent to other chemicals and ecosystems. Triazine exposure can cause changes in growth, reproduction, immune function and antioxidant status in fish (Hostovsky *et al.*, 2014). Chronic exposure to atrazine and related compounds can induce oxidative stress, endocrine disruption, genotoxicity and organ damage. According to Koutnik *et al.* (2015), triazine herbicides impair fish growth, haematological parameters, enzyme activity, and tissue morphology. Likewise, Akhtar *et al.* (2021) reported significant differences in haematological and parameters of snow trout (*Schizothorax richardsonii*), exposed to atrazine which reflect severe physiological stress. One of the mechanisms involved in triazine toxicity is oxidative stress. Oxidative stress arises from excessive production of reactive oxygen species (ROS) that overwhelms the organism’s antioxidant defence mechanisms. Oxidative stress is damaging to cellular lipids, proteins, carbohydrates and nucleic acids thus leading to cellular dysfunction and eventually death (Lushchak, 2011). Lipid peroxidation, protein oxidation, mitochondrial dysfunction, and DNA damage represent common consequences of pesticide-induced oxidative stress in aquatic organisms. The liver is an organ of particular concern because it is the predominant organ for the metabolism of xenobiotics and the formation of free radicals. Biochemical parameters such as alanine aminotransferase (ALT), aspartate aminotransferase (AST), alkaline phosphatase (ALP), acid phosphatase (ACP), lactate dehydrogenase (LDH), bilirubin, albumin, globulin, and total protein are routinely used to assess liver status in fish. Altered activities of hepatic enzymes are generally indicative of hepatocellular damage and leakage of intracellular constituents into circulation (Woo *et al.*, 2018). Deviation from normal patterns of protein metabolism and bilirubin concentration implies the same i.e. liver dysfunction and reduced physiological efficiency. Thus, biochemical evaluation of hepatic biomarkers may throw an important light on the liver toxicities of pesticides. Histopathological changes are also powerful tools to measure toxic effects on aquatic organisms. They often signify a cumulative effect of stressors in the environment and may shed more light on sublethal toxicity than some conventional approaches. Histological lesions in fish exposed to pesticides have been described by various authors (Paolini *et al.*, 2005; Kumar *et al.*, 2024) to include hepatocellular degeneration, vacuolisation necrosis, sinusoidal dilation, haemorrhage, inflammatory infiltration and the like. Cell and/or tissue structure is subsequently threatened, compromising its intrinsic functions, and eventual fish death and egg production may be imperilled. Consequently, attention has received to the role of antioxidants in ameliorating the toxic effects of environmental toxicants. Antioxidants neutralize free radicals, reduce oxidative stress and protect cellular components from deterioration. One of the most potent and efficient lipid soluble antioxidant in vivo is a

natural Vitamin E (α-tocopherol). It scavenges free radicals, prevent lipid peroxidation, stabilizes cellular membranes, improves immune ability and functions etc. (Alkaladi, 2019), and most important, this property has made it an important potential protective agent against pesticides use toxicity in aquatic organisms.

There are number of studies that evaluated the antioxidant properties of Vitamin E and its usefulness in counteracting environmental pollutants in fish. Alkaladi (2019) found that Vitamin E modulated oxidative stress and improved levels of antioxidant enzymes in Nile tilapia exposed to zinc oxide nanoparticles. Elkaradawy *et al.* (2021) Vitamin E-fortified diets in Nile tilapia on the physiological response, antioxidant status and tissue integrity. Rohani *et al.* (2022) also evaluated the potential use of Vitamin E in improving growth performance, feed utilization and health status of fish. Thus, Vitamin E may therefore take a center stage of offensive point against environmental stressors. Despite plethora of information regarding the toxicity of pesticides and the protective ability of antioxidants against these substances, little or no information are available regarding the protective capability of Vitamin E against triazine poisoning in *C. punctatus*. Most of the available studies examining the issue are generally devoted merely to haematological effects and reproductive and/or oxidative stress biomarkers, while others have touched the aspects of both histopathological and biochemical study of the transplantation of the toxic and recovery process. Hence, this study is focused on the determining the potential mechanisms of Vitamin E against triazineplantidots induced hepatotoxicity of freshwater fish. The study is however underlined by the interest of the toxic effects of herbicide particularly, triazines on hepatic function in *C. punctatus*, and the ameliorative efficacy of Vitamin E. Specifically, hepatic enzyme activities, protein metabolism and bile contents and liver histopathology in fish after exposure to triazine and those ameliorated with Vitamin E will be evaluated. Using this study, information will accrue on the aquatic toxicity of pesticides, and also form the backdrop for new strategies for environmental monitoring, fish health management, aquaculture practices, etc.

Materials and Methods

Experimental Fish- Healthy specimens of *Channa punctatus* (Bloch.) weighing 70–90 g and measuring 15–18 cm in length were collected from freshwater habitats of the Narora region, Bulandshahr, Uttar Pradesh, India. Fish were acclimatized for 14 days under laboratory conditions before experimentation. During acclimatization, fish were fed a commercial pellet diet twice daily and maintained in dechlorinated water under laboratory conditions.

Chemical and Reagents- Triazine herbicide (analytical grade, purity ≥ 98%) was procured from a certified chemical supplier and used as the experimental toxicant throughout the study. Vitamin E (α-tocopherol) was obtained from Sigma-Aldrich (USA). Commercial diagnostic kits were used for the estimation of ALT, AST, ALP, ACP, LDH, total protein, albumin, and bilirubin. All chemicals, solvents, and reagents employed in biochemical and histopathological analyses were of analytical reagent (AR) grade.

Experimental Design- The 96-hour LC₅₀ value of Triazine herbicide was determined according to OECD guidelines. A sublethal concentration equivalent to 1/10th of the LC₅₀ value was selected for chronic exposure studies.

A total of 30 healthy *Channa punctatus* were selected and randomly divided into three groups, each containing 10 fish. Group I served as control, Group II was exposed to triazine herbicide, and Group III was exposed to triazine along with Vitamin E supplementation:

Group I (Control): 10 fish

Fish maintained in pesticide-free water and fed a standard diet.

Group II (Triazine Exposed): 10 fish

Fish exposed to a sublethal concentration of Triazine herbicide.

Group III (Triazine + Vitamin E): 10 fish

Fish exposed to Triazine herbicide and supplemented with Vitamin E at a dose of 100 mg/kg feed. The exposure period was 30 days.

Blood Collection and Serum Preparation

At the end of the experimental period, fish were anaesthetized using MS-222 (tricaine methanesulfonate). Blood samples were collected from the caudal vein using sterile syringes. Blood samples were allowed to clot and centrifuged at 3000 rpm for 15 minutes. The separated serum was collected and stored at –20°C for biochemical analysis.

Hepatic Biochemical Parameters

Alanine Aminotransferase (ALT)- Serum ALT activity was

estimated by the Modified IFCC UV Kinetic Method described by Schumann *et al.* (2002).

Aspartate Aminotransferase (AST)- AST activity was measured using the IFCC UV Kinetic Method (Schumann *et al.*, 2002).

Alkaline Phosphatase (ALP)- ALP activity was determined by the PNPP-AMP Kinetic Assay Method (Young, 1997).

Acid Phosphatase (ACP)- ACP activity was estimated using the α -Naphthyl Phosphate Kinetic Method (Hillmann, 1971).

Lactate Dehydrogenase (LDH)- LDH activity was measured by the UV Kinetic Method according to Tietz (1995).

Total Protein- Total protein concentration was determined by the Biuret Method (Tietz, 1995).

Albumin-Serum albumin was estimated using the Bromocresol Green (BCG) Method described by Doumas *et al.* (1971).

Globulin- Globulin concentration was calculated as:

Globulin = Total Protein – Albumin

Albumin/Globulin Ratio (A/G Ratio) - The A/G ratio was calculated as:

$$A/G \text{ Ratio} = \text{Albumin} \div \text{Globulin}$$

Total Bilirubin- Total bilirubin was estimated by the Jendrassik-Grof Colorimetric Method (Jendrassik & Grof, 1938).

Histopathological Examination of Liver- After blood collection, fish were sacrificed and liver tissues were carefully excised. Tissue samples were fixed in 10% neutral buffered formalin for 24–48 hours.

The tissues were processed through:

- Dehydration in ascending grades of ethanol
 - Clearing in xylene
 - Embedding in paraffin wax
 - Sectioning at 5 μ m thickness using a rotary microtome
 - Staining with Hematoxylin and Eosin (H&E)
- Prepared slides were examined under a light microscope for pathological alterations including:
- Hepatocellular degeneration
 - Cytoplasmic vacuolation
 - Necrosis
 - Congestion
 - Sinusoidal dilation
 - Hemorrhage
 - Inflammatory cell infiltration
- (Bancroft & Gamble, 2019)

Statistical Analysis- Experimental data were expressed as Mean \pm Standard Error of Mean (Mean \pm SEM). Statistical analysis was performed using:

- One-Way Analysis of Variance (ANOVA)
- Tukey's Multiple Comparison Post Hoc Test using GraphPad Prism version 9.0.

Differences among groups were considered statistically significant at: $p < 0.05$.

Result

Table1: Effect of Triazine and Vitamin E on Hepatic Biomarkers of *Channa punctatus*

Parameter	Control	Triazine	Triazine + Vitamin E
ALT (U/L)	28.42 \pm 1.34 ^a	58.73 \pm 2.67 ^c	36.81 \pm 1.85 ^b
AST (U/L)	65.21 \pm 2.15 ^a	128.45 \pm 4.12 ^c	82.63 \pm 3.24 ^b
ALP (U/L)	72.84 \pm 2.18 ^a	148.73 \pm 4.25 ^c	95.64 \pm 3.14 ^b
ACP (U/L)	12.42 \pm 0.56 ^a	28.35 \pm 1.12 ^c	17.26 \pm 0.84 ^b
LDH (U/L)	245.62 \pm 8.24 ^a	512.73 \pm 14.25 ^c	321.45 \pm 10.34 ^b
Total Protein (g/dL)	5.84 \pm 0.18 ^c	3.42 \pm 0.14 ^a	4.98 \pm 0.16 ^b
Albumin (g/dL)	3.21 \pm 0.12 ^c	1.65 \pm 0.08 ^a	2.74 \pm 0.09 ^b
Globulin (g/dL)	2.63 \pm 0.10 ^b	1.77 \pm 0.07 ^a	2.24 \pm 0.08 ^{ab}
Bilirubin (mg/dL)	0.48 \pm 0.02 ^a	1.34 \pm 0.05 ^c	0.72 \pm 0.03 ^b

Values are Mean \pm SEM (n = 10). Different superscripts indicate significant differences at $p < 0.05$.

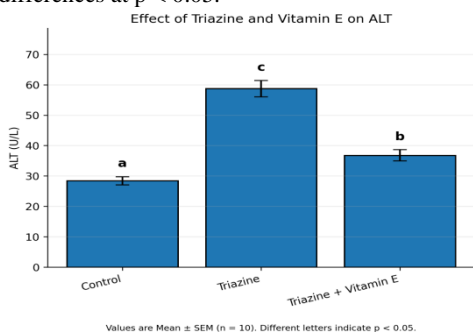


FIG:1 Triazine exposure significantly elevated serum ALT activity in *Channa punctatus*, indicating liver damage, while Vitamin E supplementation effectively reduced enzyme levels toward normal.

This is an Open Access article published under the Creative Commons Attribution 4.0 International License (CC BY 4.0)

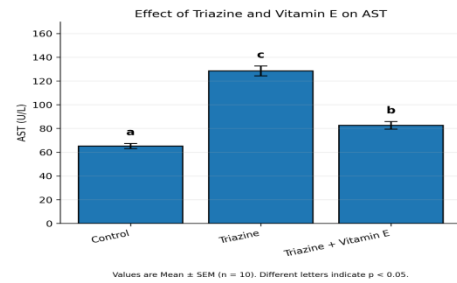


FIG:2 Triazine exposure significantly increased serum AST activity in *Channa punctatus*, indicating hepatic injury, while Vitamin E supplementation substantially restored AST levels toward normal.

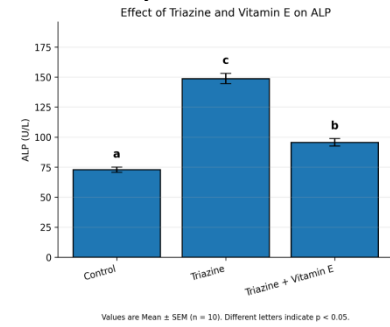


FIG:3 Triazine exposure significantly elevated serum ALP activity in *Channa punctatus*, indicating hepatic dysfunction, whereas Vitamin E supplementation markedly reduced ALP levels and improved liver function.

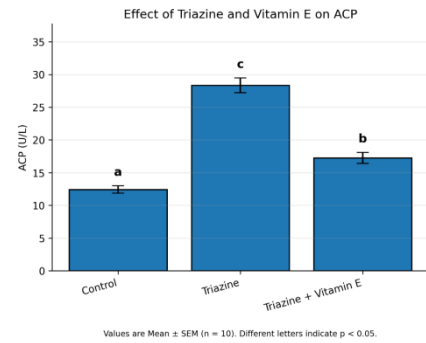


FIG:4 Triazine exposure significantly increased serum ACP activity in *Channa punctatus*, indicating lysosomal and hepatic damage, while Vitamin E supplementation effectively reduced ACP levels.

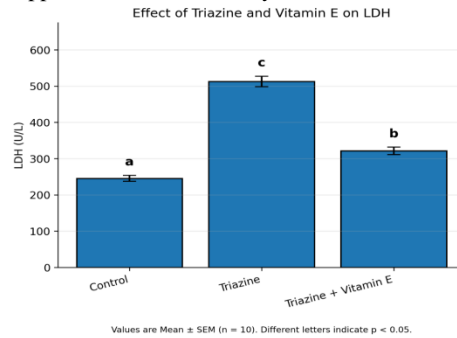


FIG:5 Triazine exposure significantly elevated serum LDH activity in *Channa punctatus*, indicating cellular necrosis and hepatic damage, while Vitamin E supplementation markedly reduced LDH levels.

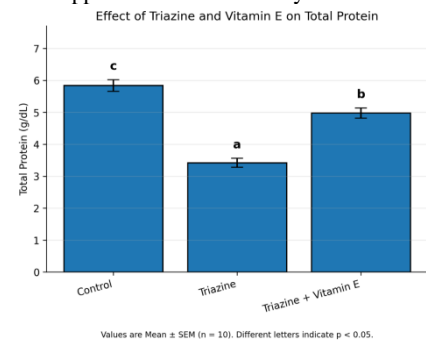


FIG: 6 Triazine exposure significantly reduced serum total protein levels in *Channa punctatus*, indicating impaired hepatic protein synthesis, whereas Vitamin E supplementation partially restored

protein concentration.

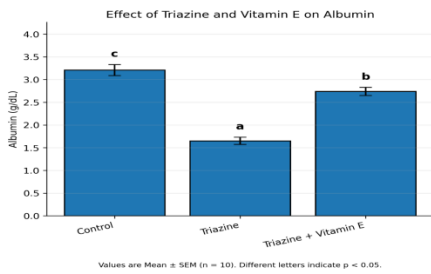


FIG:7 Triazine exposure significantly decreased serum albumin levels in *Channa punctatus*, indicating impaired liver synthetic function, while Vitamin E supplementation markedly restored albumin concentration.

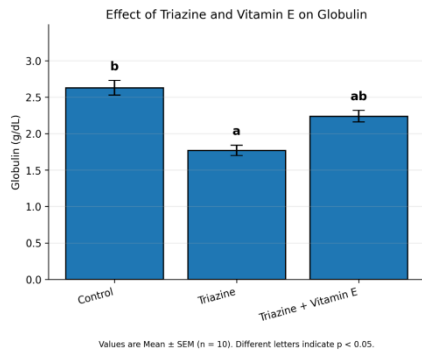


FIG:8 Triazine exposure significantly reduced serum globulin levels in *Channa punctatus*, indicating impaired immune and hepatic functions, while Vitamin E supplementation partially restored globulin concentration.

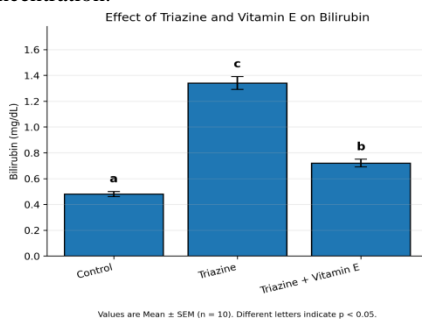


FIG:9 Triazine exposure significantly increased serum bilirubin levels in *Channa punctatus*, indicating impaired hepatic excretory function, while Vitamin E supplementation markedly reduced bilirubin concentration toward normal values.

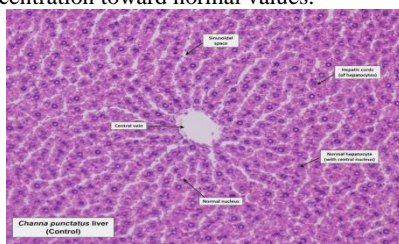


FIG:10 Histopathological section of control liver of *Channa punctatus* showing normal hepatic architecture with intact hepatocytes, centrally located nuclei, well-organized hepatic cords, sinusoids, and central vein (H&E stain, ×400).

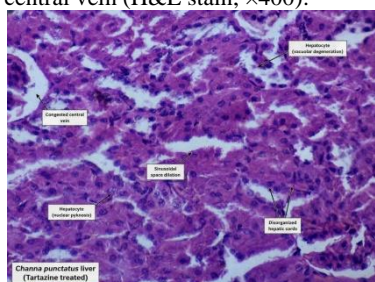


Figure 11. Histopathological section of *Channa punctatus* liver exposed to tartrazine showing hepatocellular degeneration, nuclear pyknosis, sinusoidal dilation, congestion, vacuolar changes, and disorganized hepatic cords.

Discussion

The present study demonstrates that exposure of *Channa punctatus* to triazine herbicide exerted a marked deleterious influence on the hepatic biochemical parameters and the histoarchitecture of the liver indicating severe hepatotoxicity. The highly significant increase in serum ALT, AST, ALP, ACP, LDH, and bilirubin in the triazine treated group indicates extensive liver damage, compared with control group. However, the amelioration of these changes by supplementation of Vitamin E indicates its protective role against triazine induced hepatic damage in fish. The specific release of ALT and AST into the circulation is a very sensitive indicator of liver injury and released into the blood their concentration increases after damage to cell membranes (Ube *et al.*, 2021). The significant increase in ALT and AST activity in “triazine” exposed fish is associated with leakage of intracellular contents probably as a result of degeneration and necrosis of the tissues. Earlier studies have also revealed that the activities of transaminases are increased due to the toxicity of pesticides and that this is a characteristic of pesticide exposure in fishes (Akhtar *et al.*, 2021; Woo *et al.*, 2018). The reduction of ALT and AST in the Vitamin E treated group indicates stabilization of hepatocyte membranes and recovery. The ALP activity is indicative of the full been activated after exposure to triazine pesticides, and alterations in the level of this enzyme reflects the hepato cell injury. Increased activity of phosphatases is usually observed during tissue degeneration (Tilak *et al.*, 2009). The highly significant increased activity of ALP in triazine exposed fish indicates impairment of metabolism of liver and lysosomes. However, this enzyme was reduced significantly in Vitamin E treated group to near control values. The increased levels of LDH in the triazine group relates to necrosis as a result of injury since the enzyme LDH during necrosis is released to the circulation (Koul *et al.*, 2007). The significant increases of LDH by herbicides have also been measured in fish and this is of potential use in monitoring toxic events and animal welfare (Alves *et al.*, 2010). The reduction of LDH levels in the Vitamin E treatment indicates a reduction of tissue damage as well as improvement of viability of the tissues. The decreased levels of total protein as well albumin and globulin might be impaired synthesis due to injury even as the liver is the site of protein production, damage to the cycle cells will be followed by decreased serum proteins. This has been reported earlier when fish were exposed to pesticides (Akhtar *et al.*, 2021). By contrast, the increase in these fractions in fish paralleled the healing action of Vitamin E in hepatic damage. The results of the histopathological examination corroborated the observations on the biochemical profiles. Degeneration and necrosis of the tissues are clearly illustrated by necrosis, sinusoid dilation and congestion as well as pyknosis of the nuclei (Mishra *et al.*, 2017). Similar findings were reported by Poalini *et al.* (2005); Kumar *et al.* (2024). The mechanism of protection is mediated by the role of Vitamin E. It acts by quenching reactive oxygen species and thereby maintains the optimum membrane level. It protects lipids from oxidation and radical species (Alkaladi, 2019). The implication is that Vitamin E ameliorates triazine induced hepatic damage effectively in fish.

Conclusion

The present investigation provides further evidence that triazine herbicide causes hepatotoxic effects and the changes in biochemical indices and histopathology substantiates that triazine affects liver structure and function. Enzyme activities of ALT, AST, ALP, ACP and LDH were significantly increased in serum suggesting disruption of secreting hepatocytes and subsequent leakage of intracellular components into the blood. Elevation in bilirubin and depression of total protein, albumin and globulin levels point towards hepatic dysfunction and damage to the visceral organ. The biological significance and physiological relevance of these biochemical changes indicates that triazine is a perturbant of fish physiology that seriously threatens the health of the species exposed to this toxin. The histopathological examination of liver tissues revealed distortion in morphology and function of this organ following triazine intoxication. Injured hepatic architecture was evident with hepatocellular degeneration, cytoplasmic vacuolation, pyknosis in nucleus, sinusoids dilation, and disorganization of vascular spaces. The damage indicates that the liver is under oxidative stress. Available literature suggests that liver is the prominent organ where detoxication takes place so triazine toxicity will impact largely on general physiology and growth of fish because it has a high metabolic tryptic resistant

functional capability. A significant finding of the present investigation is the strong protective influence of Vitamin E on triazine induced hepatic damage. Experimental feeding with this potent antioxidant for two weeks significantly restored altered biochemical indices to near normal & decreased the severity of tissue lesions. Recovery of hepatic enzyme activities, fractions of proteins and bilirubin levels in the liver of fish fed Vitamin E may be considered as improvement of function and recovery from cellular injury. Histological examination showed diagnostics feature of regeneration and recovery of the hepatic architecture. Vitamin E antioxidant properties may perhaps be responsible for its hepatoprotective action. The tocopherol quenches ROS and inhibits lipid peroxidation and attenuates cellular membrane (cell anchors) against reactive affects. Antioxidant based nutrition facilitates minimal cellular injury so that tissue repairs occur in fish subject to toxic stress. This suggests the important role of vitamin E in protecting fish from contaminant stress resulting from pesticide use. Triazine herbicide addressed in this investigation constitutes serious threat to fish health from resultant hepato toxicity. This study demonstrates the strong hepatoprotective potential of Vitamin E antioxidant that prevented damage to hepatic architecture and enzyme function from the deadly effects of pesticide exposure. This study will provide useful and significant information to aquatic toxicologist and environmental risk assessment professionals. Special dietary attention need be paid to fish species frequently exposed to contaminated water and tissues, and the study provides practical solutions to limiting the chemical use of pesticides by demonstrating the mitigating potential of Vitamin E in protecting aquatic biodiversity.

References

- Akhtar, N., Khan, S., Tabassum, S., & Zahran, E. (2021). Adverse effect of atrazine on blood parameters, biochemical profile and genotoxicity of snow trout (*Schizothorax plagiostomus*). *Saudi Journal of Biological Sciences*, 28(3), 2000–2003.
- Alkaladi, A. (2019). Vitamins E and C ameliorate oxidative stress induced by zinc oxide nanoparticles in *Oreochromis niloticus*. *Saudi Journal of Biological Sciences*, 26(2), 357–362.
- Austin, B. (2010). The effects of pollution on fish health. *Journal of Applied Microbiology*, 85(S1), 234S–242S.
- Bancroft, J. D., & Gamble, M. (2019). *Theory and Practice of Histological Techniques* (8th ed.). Elsevier.
- Doumas, B. T., Watson, W. A., & Biggs, H. G. (1971). Albumin standards and the measurement of serum albumin with bromocresol green. *Clinica Chimica Acta*, 31(1), 87–96.
- Elkaradawy, A. (2021). Synergistic effects of Quillaja saponaria and Vitamin E on Nile tilapia. *Aquaculture Reports*, 20, 100733.
- Hillmann, G. (1971). Determination of acid phosphatase activity. *Zeitschrift für Klinische Chemie und Klinische Biochemie*, 9, 273–274.
- Hostovsky, M., Blahova, J., Plhalova, L., Kopriva, V., & Svobodova, Z. (2014). Effects of the exposure of fish to triazine herbicides. *Neuro Endocrinology Letters*, 35(Suppl. 2), 3–25.
- Jendrassik, L., & Grof, P. (1938). Colorimetric determination of bilirubin. *Biochemische Zeitschrift*, 297, 81–89.
- Koul, P. C., Mastan, S. A., & Qureshi, T. A. (2007). Sub-lethal effect of dichlorvos on certain biochemical parameters of *Channa gachua*. *Journal of Herbal Medicine and Toxicology*, 1(2), 29–32.
- Koutnik, D., Stara, A., & Velisek, J. (2015). The effect of selected triazines on fish: A review. *Slovenian Veterinary Research*, 52(3), 107–131.
- Kumar, M., Mishra, P., Jain, R., Khan, A., & Dwivedi, P. (2024). Assessment of oxidative stress, genotoxicity and histopathological alterations in *Channa punctatus* exposed to fungicide. *Journal of Applied Biology*, 12(1), 159–164.
- Lushchak, V. I. (2011). Environmentally induced oxidative stress in aquatic animals. *Aquatic Toxicology*, 101(1), 13–30.
- Paolini, A., Berti, M., D'Angelo, A., Scortichini, G., & Giansante, C. (2005). Use of histopathological indicators in evaluating river environments. *Veterinaria Italiana*, 41(3), 189–198.
- Schumann, G., *et al.* (2002). IFCC primary reference procedures for the measurement of catalytic concentration of AST and ALT. *Clinical Chemistry and Laboratory Medicine*, 40(7), 725–733.
- Singh, B., Maheshwari, M., & Sharma, H. (2024). Nutritional studies on fish *Catla catla* found in Ganga River with hydrobiological studies. *Journal of Science Innovations and Nature of Earth*, 4, 17–22. <https://doi.org/10.59436/ht5mmg32>
- Singh, B., Sharma, H. N., Prveen, & Singh, S. (2024). A review on effect of cypermethrin on hematology of fresh water fish *Channa punctatus* (Bloch.). *Journal of Science Innovations and Nature of Earth*, 4. <https://doi.org/10.59436/jsiane.271.2583-2093>
- Tietz, N. W. (1995). *Clinical Guide to Laboratory Tests* (3rd ed.). Saunders.
- Tilak, K. S., Raju, P. W., & Butchiram, M. S. (2009). Effects of alachlor on biochemical parameters of the freshwater fish *Channa punctatus*. *Journal of Environmental Biology*, 30(3), 420–426.
- Velisek, J., Stara, A., & Svobodova, Z. (2011). The effects of pyrethroid and triazine pesticides on fish physiology. In *Pesticides in the Modern World*.
- Woo, S. I., Kim, Y., Kim, H., Ahn, J., Seo, J., Jung, S., Cho, M., & Chung, J. (2018). Toxicological effects of trichlorfon on haematological and biochemical parameters in *Cyprinus carpio*. *Comparative Biochemistry and Physiology Part C: Toxicology & Pharmacology*, 209, 18–27.
- Woo, S. I., Kim, Y., Kim, H., *et al.* (2018). Toxicological effects of trichlorfon on haematological and biochemical parameters in *Cyprinus carpio*. *Comparative Biochemistry and Physiology Part C*, 209, 18–27.
- Young, D. S. (1997). *Effects of Preanalytical Variables on Clinical Laboratory Tests* (3rd ed.). AACC Press.